

This patient has been treated with Solnatide IMP within the Compassionate Use Program in Austria at the KLINIKUM Klagenfurt am Wörthersee, Department of Anaesthesiology and Intensive Care.

Lung transplantation for COVID-19-associated acute respiratory distress syndrome in a PCR-positive patient

Christian Lang*, Peter Jaksch*, Mir Alireza Hoda, György Lang, Thomas Staudinger, Edda Tschernko, Bernhard Zapletal, Silvana Geleff, Helmut Prosch, Riem Gawish, Sylvia Knapp, Oliver Robak, Florian Thalhammer, Alexander Indra, Markus Koestenberger, Robert Strassl, Thomas Klikovits, Kamran Ali, Gottfried Fischer, Walter Klepetko, Konrad Hoetzenecker*, Peter Schellongowski*



Most patients with COVID-19 have a mild or asymptomatic disease course; however, about 10% require admission to an intensive care unit (ICU) because of acute respiratory distress syndrome (ARDS).^{1,2} Mortality rates of up to 60% have been reported for this subgroup.^{1,4} Lung transplantation remains the ultimate treatment option for various chronic end-stage lung diseases. In addition, it can be considered as a salvage therapy for carefully selected patients who have severe treatment-refractory ARDS.⁵ However, wide uncertainty exists as to whether lung transplantation could have a place in the treatment of severe COVID-19 and, if so, what the optimal timing for such a treatment should be. Herein, we report the first case of lung transplantation for a patient with a persistently positive severe acute respiratory syndrome coronavirus 2 (SARS-CoV-2) real-time RT-PCR test result.

On March 21, 2020, at a time when the first COVID-19 cases were reported in Austria, a 44-year-old woman was admitted to Klinikum Klagenfurt am Wörthersee (Klagenfurt, Austria) with symptoms of fever and cough, and tested positive for SARS-CoV-2 by nasopharyngeal swab real-time RT-PCR on the same day (day 0).

Her medical history was unremarkable, except that she had mild psoriatic arthritis, which did not require any systemic treatment, and a diagnosis of idiopathic CD4 lymphocytopenia without any clinical relevance. On day 6 after the first positive SARS-CoV-2 test, the patient's respiratory condition worsened, requiring transfer to the ICU and subsequent intubation. Therapy was further escalated by femorofemoral venovenous extracorporeal membrane oxygenation (ECMO), initiated on day 13. Administration of immunoglobulins, tocilizumab, and lopinavir, and use of prone positioning did not improve the patient's condition. On day 20, the patient developed spontaneous bleeding from the right thoracic cavity, which required surgical opening of her chest and haematoma evacuation. A small, self-limiting intracerebral bleed in the left temporal lobe did not require any intervention. During this episode of bleeding, the patient required multiple transfusions. A final treatment attempt with convalescent plasma therapy (day 32) was initiated, which offered no benefit, and the patient was subsequently transferred to the Medical University of Vienna (Vienna, Austria) on day 48 as a possible candidate for lung transplantation.

On arrival, the patient required moderate doses of vasopressors (0.3 µg/kg per min norepinephrine), presented with normal kidney function, and had a

bilirubin level of 48 µmol/L. Partial pressure of arterial oxygen was about 70 mm Hg while ventilated with airway pressure release ventilation of 25 mbar over 8 mbar positive end-expiratory pressure and a fractional concentration of oxygen in inspired air of 1.0. With these settings, her tidal volume was only around 50 mL and she was fully dependent on the venovenous ECMO support (blood flow 3.8 L/min and sweep gas flow 6 L/min). Subsequent reduction of the sedation levels led to spontaneous opening of her eyes. When turning the patient, repeated episodes of desaturation accompanied by bradycardia occurred and the ECMO cannulation had to be changed to a femorojugular configuration using larger cannulas (25F/21F). The changes to the cannulation resulted in stabilisation of the patient; however, ECMO run with regular physiotherapy while the patient was awake to avoid further deconditioning, as previously described in the setting of bridge to transplant,^{6,7} was not feasible.^{6,7} A complete investigation was initiated to consider the possibility of lung transplantation.

Pulmonary CT angiography revealed complete consolidation of the lungs with large necrotic areas and air inclusions, raising high suspicion of bacterial superinfection. Additionally, there was almost no perfusion in large parts of the lower lobes, suggesting extensive infarctions of the peripheral parts of the lung parenchyma and thrombosis of small and medium-sized pulmonary arteries (figure 1). CT of the CNS showed a reduction in the size of the lesion corresponding to the previously reported small left-temporal haemorrhage. On day 52, an increase of acute-phase proteins and a positive *Candida albicans* blood culture were noted. Furthermore, bilirubin increased to 170 µmol/L, so a superinfection of the necrotic lung with subsequent sepsis-associated liver dysfunction was assumed (appendix p 4).

During the whole course of treatment from day 0, RT-PCR testing for SARS-CoV-2 was repeatedly positive, both in nasopharyngeal swabs and in bronchoalveolar lavage samples (figure 2). However, real-time RT-PCR cycle threshold (Ct) values were exceptionally high, with some values greater than 33, suggesting that these positive results could have derived from nucleic acid segments of residual virus without actual infectivity.⁸ To better define the presence of an active SARS-CoV-2 infection, Vero cell cultures were used,⁹ which turned out to be negative after 7 days of culture (three passages).

Analyses for pre-existing antibodies showed high levels of class I and class II HLA antibodies, probably due to the previous administration of multiple blood products,

Lancet Respir Med 2020

Published Online

August 25, 2020

[https://doi.org/10.1016/S2213-2600\(20\)30361-1](https://doi.org/10.1016/S2213-2600(20)30361-1)

See Online/Comment

[https://doi.org/10.1016/S2213-2600\(20\)30393-3](https://doi.org/10.1016/S2213-2600(20)30393-3)

*Contributed equally

Division of Thoracic Surgery, Department of Surgery, (C Lang MD, P Jaksch MD, M A Hoda PhD, G Lang PhD, T Klikovits PhD, K Ali MD, Prof W Klepetko MD, K Hoetzenecker PhD), Intensive Care Unit 1312, Department of Medicine I (T Staudinger MD, O Robak MD, P Schellongowski MD), Division of Cardiac, Thoracic and Vascular Anesthesia and Intensive Care (Prof E Tschernko MD, B Zapletal MD), Clinical Institute of Pathology (S Geleff MD), Department of Biomedical Imaging and Image-guided Therapy (H Prosch MD), Research Laboratory of Infection Biology, Department of Medicine I (R Gawish PhD, Prof S Knapp PhD), Division of Infectious Diseases and Tropical Medicine, Department of Medicine I (Prof F Thalhammer MD), Division of Clinical Virology, Department of Virology (R Strassl MD), and Department of Blood Group Serology and Transfusion Medicine (G Fischer MD), Medical University of Vienna, Vienna, Austria; CeMM, Research Center for Molecular Medicine of the Austrian Academy of Sciences, Vienna, Austria (R Gawish, Prof S Knapp); Institute for Microbiology and Hygiene, Austrian Agency for Health and Food Safety, Vienna, Austria (A Indra MD); and Department of Anaesthesiology and Intensive Care, Klinikum Klagenfurt am Wörthersee, Klagenfurt, Austria (M Koestenberger MD)

Correspondence to: Dr Konrad Hoetzenecker, Division of Thoracic Surgery, Department of Surgery, Medical University of Vienna, A-1090 Vienna, Austria. konrad.hoetzenecker@meduniwien.ac.at
See Online for appendix

including convalescent plasma. Cytological analysis of bronchoalveolar lavage fluid exposed predominantly necrotic material, and flow cytometric analysis showed the absence of alveolar macrophages but high abundance of immature neutrophils and cell debris (appendix p 2). These findings further corroborated the profound damage to the lungs.

On the basis of all these examinations, a comprehensive interdisciplinary discussion on the direction of treatment was held on day 52, which resulted in a consensus that the lungs of the patient had no potential for recovery. Consequently, the alternatives of terminating the treatment or proceeding to lung transplantation were discussed, which resulted in the final decision in favour of transplantation. This decision was based on the following considerations: (1) virus culture was negative and real-time RT-PCR Ct values were high; (2) it was more than 5 weeks since the start of the SARS-CoV-2 infection; (3) no alternative treatment options were available; (4) the case was a single-organ failure in a young patient; (5) it was a pre-septic condition originating from the lungs; and (6) there were no other obvious barriers for long-term recovery. As the patient could not consent to the procedure, next-of-kin consent was obtained from her spouse. She was put on the waiting

list on day 52 and was granted a lung allocation score of 49.3. Daily immunoabsorption therapy was initiated, with the aim of achieving desensitisation of the patient (ie, removal of preformed antibodies from the circulation) before transplantation (appendix p 4).

On day 58, a suitable donor organ became available and a sequential bilateral lung transplantation was performed. Intraoperatively, a central venoarterial ECMO circuit was installed and the venovenous ECMO was kept running in parallel with a reduced flow of 1 L/min. Without clear anatomical borders, only extrapleural mobilisation of the lungs was possible. The implantation was equally challenging because of the remarkably fragile tissue quality of the recipient's bronchus and vessels, most likely due to a spread of the infectious process (ie, inflammatory changes resulting from the previous infection) to these tissues. Meticulous haemostasis was performed; nevertheless, a total of 30 units of packed red blood cells and five units of platelets were required to establish coagulation. At the end of the procedure, signs of incipient reperfusion oedema were observed, so the central venoarterial ECMO support was switched to prolonged peripheral femorofemoral venoarterial ECMO and venovenous ECMO was removed.¹⁰

The patient was transferred to the ICU in a stable condition and was put into prone position to relieve the lower lobes of the lungs. Reopening of the chest was indicated on postoperative day 1 for haematoma evacuation. Thereafter, the patient quickly recovered, the venoarterial ECMO system could be removed on postoperative day 3 and primary graft dysfunction grading at 72 h was 0.

Standard triple immunosuppression was initiated, including tacrolimus, mycophenolate mofetil, and steroids. As the patient was highly presensitised, six additional treatment cycles of immunoabsorption were done and antithymocyte globulin was administered. As expected, the crossmatch between donor and recipient was positive; however, in serial blood samples taken after transplantation, class II donor-specific antibodies were substantially reduced and class I donor-specific antibodies were completely absent (appendix p 3).

Similar to most recipients bridged to their transplant for a long time, the further postoperative course of the patient was characterised by slow recovery. From day 72 after the initial positive SARS-CoV-2 test (postoperative day 14), the patient was regularly mobilised to sitting at the edge of the bed, and on day 83 (postoperative day 25), the patient was able to speak via a tracheal multifunction cannula. She was able to be transferred to a non-ICU ward on day 121 (postoperative day 63), was able to walk with some assistance, and was recovering from neuromuscular deconditioning. At this stage, no functional impairments related to the cerebral bleeding were apparent. Cellular analysis of bronchoalveolar lavage samples confirmed regular recovery with mainly viable cells, an increasing abundance of alveolar

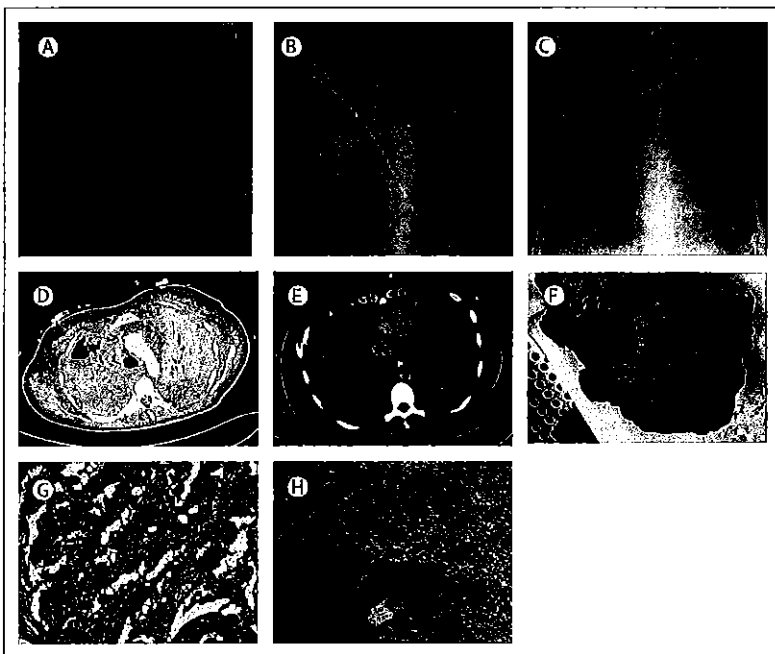


Figure 1: Radiological imaging and pathological examinations

Chest x-rays of the patient on day 6 after the initial SARS-CoV-2-positive PCR result, on admission to the intensive care unit (A); and on day 52, when she was put on the transplantation waiting list (B). Chest x-ray after lung transplantation on day 62 (postoperative day 4; C). CT on day 49 showed air-filled cystic spaces, indicating necrotic lung tissue (D); and missing contrast enhancement in the periphery of the right lower lobe, suggesting thrombosis of small pulmonary vessels (E). Macroscopic appearance of the explanted lungs showed extensive necrosis (F). Microscopic images of haematoxylin and eosin staining of the explanted lungs showed diffuse alveolar damage, inflammatory granulation (original magnification $\times 40$; G) and thrombosis of middle-sized arteries (original magnification $\times 16$; H). SARS-CoV-2=severe acute respiratory syndrome coronavirus 2.

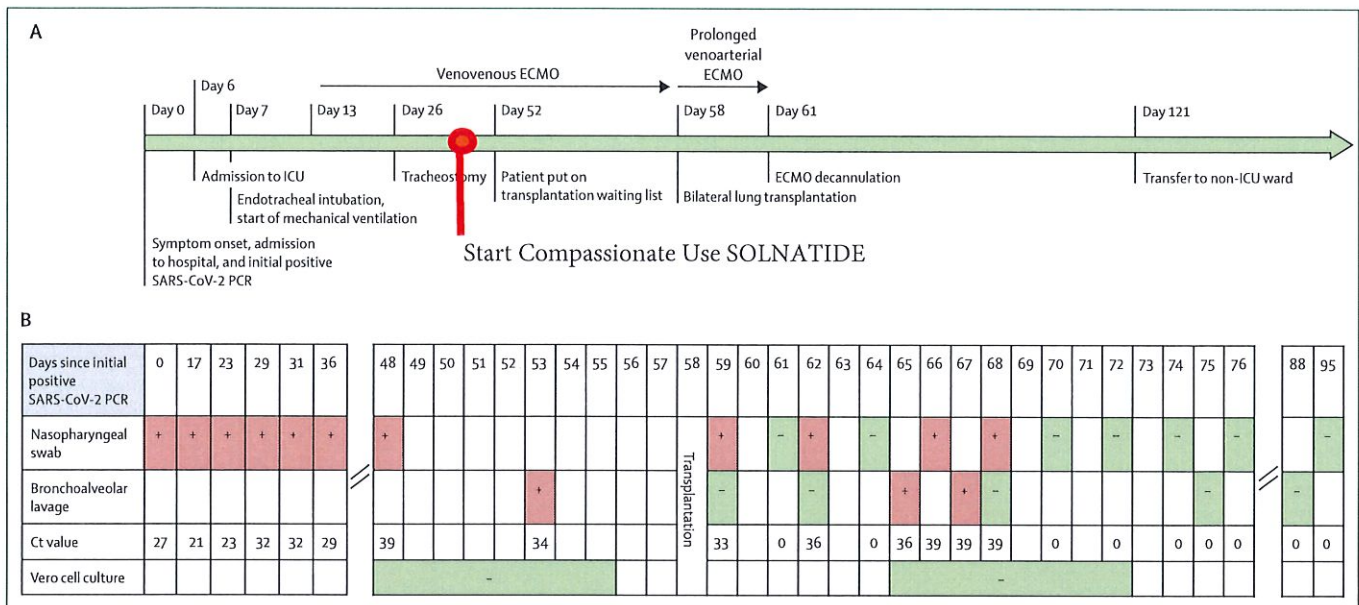


Figure 2: Patient timeline

(A) Clinical events. (B) SARS-CoV-2 tests, including PCR and Vero cell culture. Ct=cycle threshold. ECMO=extracorporeal membrane oxygenation. ICU=intensive care unit. SARS-CoV-2=severe acute respiratory syndrome coronavirus 2.

macrophages, and the presence of mature neutrophils (appendix p 2).

Notably, real-time RT-PCR for SARS-CoV-2 was performed regularly after the transplantation and remained positive in samples from nasopharyngeal swabs and bronchoalveolar lavage until postoperative day 10, but was negative thereafter. In addition, a second Vero cell culture from a bronchoalveolar lavage sample retrieved on postoperative day 7 was negative and thus confirmed absence of infectivity in the patient.

Pathological examination of the explanted lungs showed large zones of necrosis almost completely taking up both lower lobes and large areas of the upper lobes. A large proportion of alveoli were destroyed and replaced by granulation tissue, corresponding to massive diffuse alveolar damage. Throughout all lobes, remnants of substantial widespread thromboembolism were present (figure 1).

To our knowledge, available evidence for lung transplantation in COVID-19 is limited to two preliminary reports from China, suggesting that this treatment might be an option for SARS-CoV-2 PCR-negative patients.^{11,12} The case we present here extends the reports from China by showing that lung transplantation can be done in patients with positive RT-PCR results, provided that Vero cell cultures confirm non-infectivity. Of the cases reported so far through the scientific literature and the media, ours seems to represent the first successful lung transplantation of a patient with COVID-19 outside of China.

According to WHO guidelines, laboratory confirmation of SARS-CoV-2 is defined as positive RT-PCR of a nasal or pharyngeal swab.¹³ However, an increasing body of

evidence shows that PCR positivity can persist for several days or even weeks beyond virus infectivity.¹⁴ A study by Bullard and colleagues⁹ showed that SARS-CoV-2 infectivity was restricted mainly to patients with a duration of symptoms shorter than 8 days and low RT-PCR Ct values (<24). Although Vero cell cultures are not yet universally available, they are considered the gold standard to establish virus infectivity.

At day 144, the patient remained well. Despite the success of this case, it is important to emphasise that lung transplantation is an option for only a small proportion of patients with COVID-19. Many patients with COVID-19 who are admitted to the ICU are older than the acceptable age limit for the procedure or have other comorbidities that might preclude them from lung transplantation.

Furthermore, it has been shown that even patients with severe COVID-19-related ARDS have some potential to recover.¹⁵ As donor organs are a scarce resource, it is important to consider lung transplantation only for patients with irreversibly damaged lungs. In our case, a complete absence of pulmonary gas exchange after 5 weeks of venovenous ECMO, extensive signs of necrosis, and thrombotic occlusions of peripheral vessels on CT angiography, as well as highly abnormal bronchoalveolar lavage cytology, suggested that the patient was a good candidate for transplantation. This judgment was later confirmed by pathological examination of the explanted lungs.

The critical status of a patient with such extensive lung damage, the permanent risk of bacterial superinfection, and the imminent muscle loss are strong arguments

to consider lung transplantation early, certainly before an already complex situation becomes completely unmanageable. In our opinion, it is therefore highly unlikely that a strategy of rehabilitation on ECMO first and lung transplantation at a later point would have resulted in an acceptable clinical outcome. Furthermore, it is important to make full use of such short-lived opportunities for critically ill patients, and SARS-CoV-2 RT-PCR positivity alone should not exclude them from lung transplantation when it is the only remaining potentially successful therapy.

This Case Report shows that lung transplantation should be added to the armamentarium of therapies for patients with COVID-19-related ARDS. The criteria applied herein for patient selection and timing of lung transplantation need to be validated in future studies.

Contributors

CL, PJ, PS, WK, and KH drafted the report. MAH, GL, TK, KA, TS, ET, BZ, OR, and MK were involved in the treatment of the patient. SG, HP, RG, and SK acquired, analysed, and interpreted pathology specimens, radiology images, or cytology specimens. FI, AI, and RS analysed and interpreted virology data. GF interpreted donor-specific antibody tests. All authors were responsible for critical revision of the manuscript and approved the final version before submission.

Declaration of interests

We declare no competing interests.

References

- Huang C, Wang Y, Li X, et al. Clinical features of patients infected with 2019 novel coronavirus in Wuhan, China. *Lancet* 2020; 395: 497–506.
- Remuzzi A, Remuzzi G. COVID-19 and Italy: what next? *Lancet* 2020; 395: 1225–28.
- Yang X, Yu Y, Xu J, et al. Clinical course and outcomes of critically ill patients with SARS-CoV-2 pneumonia in Wuhan, China: a single-centered, retrospective, observational study. *Lancet Respir Med* 2020; 8: 475–81.
- Arentz M, Yim E, Klaff L, et al. Characteristics and outcomes of 21 critically ill patients with COVID-19 in Washington state. *JAMA* 2020; 323: 1612–14.
- Chang Y, Lee SO, Shim TS, et al. Lung transplantation as a therapeutic option in acute respiratory distress syndrome. *Transplantation* 2018; 102: 829–37.
- Benazzo A, Schwarz S, Frommlet F, et al. Twenty-year experience with extracorporeal life support as bridge to lung transplantation. *J Thorac Cardiovasc Surg* 2019; 157: 2515–25.e10.
- Hoetzenecker K, Donahoe L, Yeung JC, et al. Extracorporeal life support as a bridge to lung transplantation—experience of a high-volume transplant center. *J Thorac Cardiovasc Surg* 2018; 155: 1316–28.e1.
- He X, Lau EHY, Wu P, et al. Temporal dynamics in viral shedding and transmissibility of COVID-19. *Nat Med* 2020; 26: 672–75.
- Bullard J, Dust K, Funk D, et al. Predicting infectious SARS-CoV-2 from diagnostic samples. *Clin Infect Dis* 2020; published online May 22. <https://doi.org/10.1093/cid/ciaa638>.
- Hoetzenecker K, Benazzo A, Stork T, et al. Bilateral lung transplantation on intraoperative extracorporeal membrane oxygenator: an observational study. *J Thorac Cardiovasc Surg* 2020; 160: 320–27.e1.
- Chen JY, Qiao K, Liu F, et al. Lung transplantation as therapeutic option in acute respiratory distress syndrome for coronavirus disease 2019-related pulmonary fibrosis. *Chin Med J* 2020; 133: 1390–96.
- Han W, Zhu M, Chen J, et al. Lung transplantation for elderly patients with end-stage COVID-19 pneumonia. *Ann Surg* 2020; 272: e33–34.
- No authors listed. Covid-19: why test? Who to test? How to test? *Bull Acad Natl Med* 2020; published online May 13. <https://doi.org/10.1016/j.banm.2020.05.006>.
- Wölfel R, Corman VM, Guggemos W, et al. Virological assessment of hospitalized patients with COVID-2019. *Nature* 2020; 581: 465–69.
- Falcoz PE, Monnier A, Puyraveau M, et al. Extracorporeal membrane oxygenation for critically ill patients with COVID-19-related acute respiratory distress syndrome: worth the effort? *Am J Respir Crit Care Med* 2020; 202: 460–63.

© 2020 Elsevier Ltd. All rights reserved.

AKH Wien


Covid-19: Erste Lungentransplantation Europas in Wien

24.05.2020 um 14:52

Die 45-jährige Covid-19-Patientin aus Kärnten wäre aufgrund eines schweren Lungenversagens sonst nicht mehr zu retten gewesen.

An der MedUni Wien/AKH Wien ist am vergangenen Montag erstmals in Europa an einem Covid-19-Erkrankten eine Lungentransplantation durchgeführt worden. Die 45-jährige Patientin wäre aufgrund eines schweren Lungenversagens sonst nicht mehr zu retten gewesen. Der Eingriff war daher dringend notwendig, aber auch höchstkompliziert. Der Kärntnerin ist eine knappe Woche danach auf dem Weg der Besserung.

"Aus unserer Sicht geht es ihr jetzt hervorragend, wir haben kein gravierendes Problem bisher. Sie wacht jetzt langsam auf", sagte Walter Klepetko, der Leiter der Universitätsklinik für Chirurgie und Leiter der Klinischen Abteilung für Thoraxchirurgie der MedUni Wien/AKH Wien, am Sonntag im Gespräch mit der APA - Austria Presse Agentur. "Die Organe funktionieren alle, wir sind alle zufrieden. Aber der Weg wird schon noch länger sein, bis wir sie hoffentlich endlich aus dem Krankenhaus herausbringen werden."



Der Augusta-Bell-Hubschrauber mit Notfallpatientin landet auf dem Dach des Wiener AKH. (Bild: AKH Wien)

Als die Patientin mit dem Hubschrauber des Österreichischen Bundesheeres zu uns ins AKH kam, war ihr Zustand schon sehr kritisch. Es stellte sich zum Glück heraus, dass die anderen Organe weitgehend funktionierten und keine aktiven Viruspartikel mehr vorhanden waren. So konnte sie für eine Spenderlunge auf die Warteliste gesetzt werden.

Univ.-Prof. Dr. Walter Klepetko, Leiter der Klin. Abteilung für Thoraxchirurgie, MedUni Wien

Erst ein zweites Organangebot stellte sich als passend heraus, sodass die Operation am 18. Mai stattfinden konnte. Mit Erfolg, der Patientin geht es von Tag zu Tag besser.

Wie findet man aber ein geeignetes Spenderorgan?

Verantwortlich für die Zuteilung von Organen ist die Stiftung Eurotransplant, eine zertifizierte Service-Organisation, über ein gemeinsames Meldesystem und eine zentrale Warteliste. Nur unter bestimmten medizinischen Voraussetzungen (Übereinstimmungsmerkmale) zwischen Spender und Empfänger ist eine Transplantation möglich. Die Österreicherin stellt in mehrfacher Hinsicht eine Besonderheit dar - geht sie doch als 2000. Patientin mit einer neuen Lunge in die Geschichte des Lungentransplantationszentrums der MedUni Wien ein.

(Bild: stock.adobe.com)

ORF.at

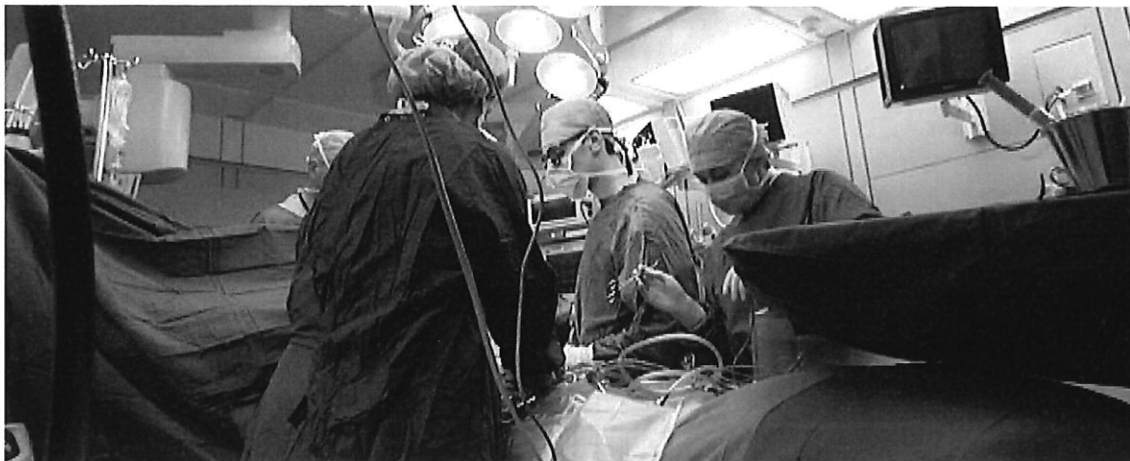

Foto: ORF
Foto: ORF

GESUNDHEIT

Lungentransplantation rettete CoV-Patientin

Im Wiener AKH ist einer Covid-19-Patientin, deren Lunge schon schwer geschädigt war, eine neue Lunge transplantiert worden. Dieser Eingriff wurde erstmals in Europa durchgeführt. Der Gesundheitszustand der Frau hat sich laut AKH nun wesentlich verbessert.

Ohne neue Lunge hätte die 45-jährige Kärntnerin laut den Ärzten keine Überlebenschance gehabt, wie die Kronenzeitung (Sonntag-Ausgabe) berichtete. Ein AKH-Sprecher bestätigte den Bericht gegenüber Radio Wien. Sämtliche Behandlungsversuche halfen demnach nichts – weder Medikamente noch eine Blutplasmatherapie. Der Zustand der Patientin, die keine Vorerkrankungen hatte, verschlechterte sich zusehends. Die Lunge versagte.

Premiere in Europa

Die AKH-Ärzte entschieden sich daraufhin für eine Lungentransplantation. Erst ein zweites Organangebot stellte sich als passend heraus. Als das Spenderorgan am Montag eintraf, konnte die Sauerstoffversorgung der Coronavirus-Patientin nur noch mit einer künstlichen Pumpe aufrecht erhalten werden. Die Transplantation war heikel, wurde in Europa noch nie an Covid-19-Patienten durchgeführt. Bekannt sind lediglich zwei Lungentransplantationen an Covid-19-Patienten in China. Von da gab es laut AKH aber keine Erfahrungswerte.

Als besonders heikel gilt die Transplantation, weil Medikamente gegen eine Abstoßungsreaktion gegeben werden mussten, die die Immunabwehr unterdrücken – bei einer hochinfektiösen Erkrankung sehr riskant. Die Transplantation verlief jedoch erfolgreich. Die Frau befindet sich laut AKH bereits auf dem Weg der Besserung.

„Lunge war wie ein Klotz“

„Aus unserer Sicht geht es ihr jetzt hervorragend, wir haben kein gravierendes Problem bisher. Sie wacht jetzt langsam auf“, sagte Walter Klepetko, der Leiter der Universitätsklinik für Chirurgie und Leiter der Klinischen Abteilung für Thoraxchirurgie der MedUni Wien/AKH Wien, am Sonntag.




Foto: APA/Georg Hochmuth

Die Transplantation ist laut dem Mediziner Walter Klepetko unter äußerst schwierigen Umständen erfolgt

Die Patientin war nach Informationen der MedUni Wien/AKH Wien ohne Vorerkrankungen und vor der vor acht Wochen erfolgten Coronavirus-Infektion bei bester Gesundheit gewesen. Das habe letztlich zum positiven Verlauf der Transplantation beigetragen. Bald nach der Erkrankung hatte sich der Zustand der Frau so sehr verschlechtert, dass sie beatmet werden musste. „Die Lage war aussichtslos. Die Lunge war wie ein Klotz, da war nichts mehr über“, sagte Klepetko auf.

Mit Heereshubschrauber ins AKH geflogen

Es entwickelte sich bei der 45-Jährigen ein Totalversagen der Lunge, sodass sie nicht mehr künstlich beatmet werden konnte und nur noch durch eine Kreislaufpumpe (ECMO – Extracorporale Membran Oxygenation) am Leben gehalten wurde. „Drei, vier Wochen ist sie an dieser Pumpe gehangen“, so Klepetko. Die Entscheidung zur Transplantation wurde schließlich gefällt, da keine Chance auf Erholung der Lunge bestand und die anderen Organe der Kärntnerin einigermaßen einwandfrei funktionierten.

Eine Woche vor dem Eingriff war die Frau aus Klagenfurt mit einem Blackhawk-Helikopter des österreichischen Bundesheeres nach Wien auf die Intensivstation gebracht worden. Zu diesem Zeitpunkt waren in ihrem PCR-Test noch Coronaviruspartikel feststellbar, die jedoch nicht mehr als infektiös eingestuft wurden.

Sehr schwierige Umstände

Laut Klepetko kommt bei einem vier Wochen an der Blutpumpe gehangenen Patienten einiges durcheinander. „Die Blutgerinnung funktioniert nicht, es gibt massive Gerinnungsprobleme bei der Transplantation. Man braucht viel mehr Konserven als normal.“ Auch musste mehrfach eine Art Blutwäsche durchgeführt werden, um Antikörper aus dem Blut herauszuwaschen. „Das ist nicht die Arbeit einer Person, nicht die meines Teams, sondern eines viel größeren Teams. Der Aufwand ist apokalyptisch hoch – aber es zahlt sich aus.“

Die Umstände waren laut Klepetko äußerst schwierig. „Die Patientin hatte keine ausreichende Zahl an Blutplättchen, und da auch Antikörper nachweisbar waren, mussten diese mittels Immunapherese zuerst ausgewaschen werden, damit sie das Organ nicht abstößt.“ Auch beim Transport der Lunge und bei der Vorbereitung auf die Operation hätten insbesondere wegen der erforderlichen Covid-19-Logistik mit den entsprechenden Schutzmaßnahmen erschwerte Bedingungen geherrscht.